

## Phacoemulsification in eyes with corneal opacification

Ayad A. Farjo, MD, Roger F. Meyer, MD, Qais A. Farjo, MD

---

We describe a technique in which transcorneal illumination with a fiber-optic light probe is used to safely perform phacoemulsification in cataractous eyes with dense corneal opacification. The technique was used in 3 eyes of 3 patients. No surgical complications occurred, and all eyes had improved visual acuity. Indications and further refinement of the technique and instrumentation are discussed.

*J Cataract Refract Surg* 2003; 29:242–245 © 2003 ASCRS and ESCRS

---

Although phacoemulsification is routinely used for cataract extraction, there are instances in which alternative approaches provide better safety or outcomes. One circumstance is when severe corneal opacification limits visualization of anterior segment structures. Frequently, the best method of visual rehabilitation is a triple procedure; that is, penetrating keratoplasty (PKP) combined with cataract extraction and intraocular lens (IOL) implantation. Although current rates of success with corneal transplantation are generally high, there is a greater risk of complications and delayed visual rehabilitation than with cataract surgery alone. In a subset of

patients, it is preferable to attempt cataract extraction primarily and perform PKP secondarily or consecutively if needed. In particular are patients at higher risk for complications during PKP in whom an acceptable amount of visual improvement can be expected with cataract extraction alone.

For more than 25 years, vitreoretinal surgeons have recognized the difficulty of operating through cloudy corneas and cataracts. Direct coaxial or para-axial illumination from the operating microscope causes scatter and reflection of light off the cornea, limiting the surgeon's view and reducing the depth of field.<sup>1</sup> Transscleral or intravitreal illumination with a fiber-optic light pipe can improve contrast and resolution 2- to 4-fold over direct coaxial or para-axial illumination through a cloudy lens or cornea.<sup>2</sup> More recently, anterior segment surgeons have used oblique fiber-optic illumination to more safely create a continuous curvilinear capsulorhexis in eyes with mature cataract.<sup>3–6</sup> This approach can be carried further to facilitate the entire cataract extraction and IOL implantation procedure through an opacified cornea. Transcorneal illumination with a fiber-optic light pipe can minimize aberrant reflection and scatter, resulting in improved visualization of anterior segment structures (Figure 1).

---

*Accepted for publication April 23, 2002.*

*From the Cornea, External Diseases, and Refractive Surgery Services, University of Iowa Hospitals and Clinics, and Department of Ophthalmology and Visual Sciences, University of Iowa, Iowa City, Iowa (A. Farjo), and Cornea, External Diseases, and Refractive Surgery Services, University of Michigan, Department of Ophthalmology and Visual Sciences, W.K. Kellogg Eye Center, Ann Arbor, Michigan (Q. Farjo, Meyer), USA.*

*Presented in part at the University of Michigan 17th Annual Department of Ophthalmology and Visual Sciences Research Symposium, Ann Arbor, Michigan, USA, March 2001.*


*Supported in part by a fellowship from the Heed Ophthalmic Foundation (Dr. A. Farjo).*

*None of the authors has a financial or proprietary interest in any material or method mentioned.*

*Reprint requests to Qais A. Farjo, MD, University of Michigan, Department of Ophthalmology and Visual Sciences, W.K. Kellogg Eye Center, 1000 Wall Street, Ann Arbor, Michigan 48105, USA.*

### Surgical Technique

The eye is anesthetized; peribulbar or retrobulbar block may be preferable given the increased surgical



**Figure 1.** (Farjo) Coaxial illumination with corneal opacity induces scatter and reflection (*left*) that can be minimized by transcorneal illumination with a fiber-optic light probe (*right*).

complexity, although topical or general anesthesia can be used.

The operating microscope is brought over the eye, and attempts are made in positioning (ie, the patient or tilt of the microscope) or lighting (ie, intensity or direction) to optimize visualization. If significant opacity exists, the microscope illumination is extinguished and a fiber-optic light probe is placed on various locations on the cornea (usually at a 45-degree angle in the periphery) until the location of optimal illumination is determined. Although anterior segment structures can be viewed with indirect illumination (via a red reflex), direct illumination typically provides better visualization. During the procedure, the light probe is held by the surgeon's nondominant hand or by an assistant. As the light probe may need regular repositioning for optimal viewing, surgeon control of positioning is preferable.

Hydrodissection and cortical cleaving are meticulously performed as a fluid wave is difficult to visualize. The lens is emulsified using the surgeon's preferred method. With 2-handed techniques, a skilled assistant may be needed to hold the light probe during nuclear cracking and fragment removal. Upon removal of the cataract, an improvement in the red reflex may allow IOL implantation with microscope illumination alone; however, transcorneal illumination helps confirm in-the-bag placement of the IOL.

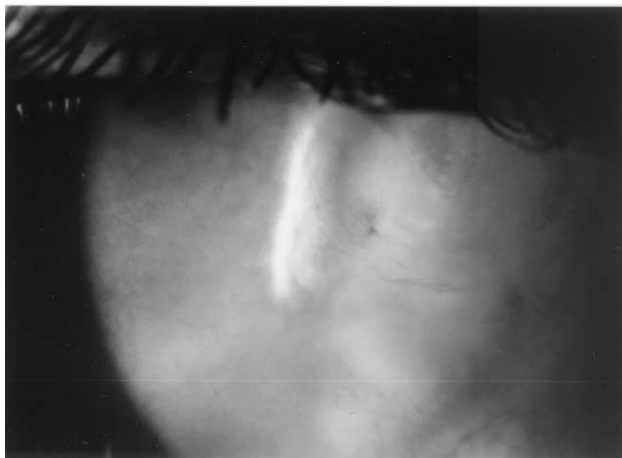
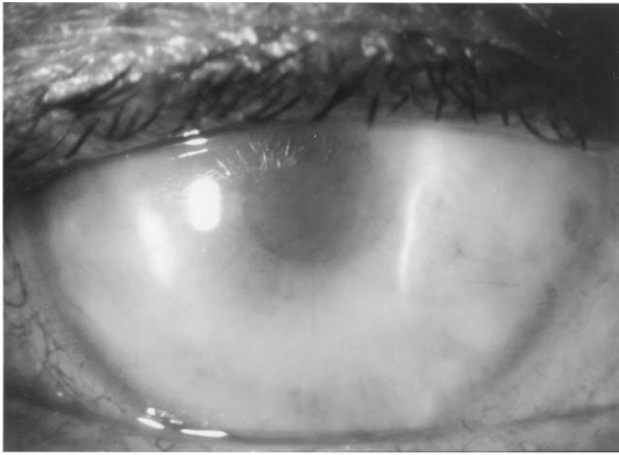
## Case Reports

### Case 1

A 62-year-old man with acne rosacea and atopic keratoconjunctivitis noted gradual loss of visual acuity in the right eye over 2 to 3 years. He had a triple procedure in the left eye for cataract and corneal scarring in December 1997. Preoperatively, the best corrected visual acuity (BCVA) in the right eye was 20/60 and in the left eye, 20/20. Brightness testing decreased the visual acuity to counting fingers (CF) at 2 feet in the right eye. Slitlamp biomicroscopy of the right eye revealed diffuse corneal opacification and a marked nuclear sclerotic cataract. The patient was hesitant to have another corneal transplantation. Cataract extraction as described above was performed in December 2000. Six weeks postoperatively, the uncorrected visual acuity was 20/30 and the BCVA, 20/20. Brightness testing decreased the visual acuity to 20/25. Despite the presence of corneal scarring (Figure 2), the patient subjectively preferred the quality of vision in the right eye to that in the left eye.

### Case 2

A 41-year-old man with corneal scarring in the left eye secondary to herpes simplex virus keratitis complicated by bacterial superinfection (*Enterobacter* species) developed a marked nuclear sclerotic and posterior subcapsular cataract. The BCVA in the left eye preoperatively was CF at 4 feet. The patient was anxious about having a corneal transplantation; therefore, cataract extraction alone with the above technique was performed in February 2000; the BCVA improved to 20/80. The patient was satisfied with this level of visual acuity for the first postoperative year but subsequently desired further improvement. Penetrating keratoplasty was performed in



**Figure 2.** (Farjo) Postoperative photographs of Case 1. Diffuse corneal scarring is present.

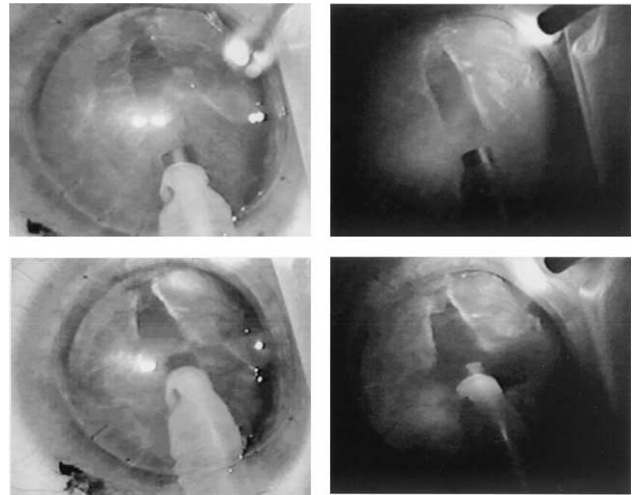
March 2001; 3 months postoperatively, the BCVA was 20/40.

### Case 3

A 64-year-old woman who had PKP in the left eye for keratoconus developed herpes simplex immune stromal keratitis and resultant scarring of the transplant. She was content with her vision in that eye until a moderate nuclear sclerotic cataract developed. Preoperatively, BCVA was 20/100. After cataract extraction using the described technique (Figure 3) in March 2000, the BCVA improved to 20/50. The patient was satisfied with this level of visual acuity and did not require further surgical intervention.

## Discussion

Factors that increase the difficulty of removing a cataract in eyes with corneal opacities include not only the extent of scarring but also the location, density, and presence of thinning, which may induce distortion.



**Figure 3.** (Farjo) Intraoperative photographs of Case 3. Coaxial illumination (*left*) and corresponding transcorneal fiber-optic illumination (*right*) are shown. The depth of field is significantly improved with transcorneal illumination.

Poor visualization can preclude safe phacoemulsification using conventional microscope illumination, necessitating alternative techniques such as transcorneal fiber-optic illumination. The impact of corneal opacity on visual acuity varies, as the above cases illustrate, and the physician and patient can better assess the need for PKP after cataract extraction. We have found that the best candidates for cataract extraction without PKP are those with documented worsening of visual acuity and cataract with unchanging corneal opacity.

As shown in the cases we describe, PKP can be delayed or not performed. This consideration is especially important in patients who are monocular, are poor candidates for PKP, or both. Patients who are at a relatively higher risk for having PKP include those with a history of multiple graft rejection and severe ocular surface disease and those who are at risk for expulsive hemorrhage (eg, advanced age, hypertension, previous surgery, glaucoma, history of expulsive hemorrhage). Monocular patients may benefit from avoiding the risks associated with more extensive surgery as well as the recovery period, during which poor vision would affect independence and quality of life. Similarly, patients may choose limited improvement in visual acuity if the prolonged rehabilitation and high refractive error often associated with PKP are eliminated. This technique may avoid postoperative astigmatism and, if combined with appropriate incision placement and limbal relaxing incisions,

can reduce preoperative astigmatism. Alternatively, this technique can be used in conjunction with PKP to make the standard triple procedure safer<sup>7</sup> or to reduce phototoxicity.<sup>8</sup>

The disadvantages of this method are that it is technically challenging and relatively time consuming. The presence of a skilled assistant may be necessary, especially with 2-handed phacoemulsification techniques. Although not encountered in our initial experience with this technique, complications such as vitreous loss may present. As we commonly use transcorneal illumination for anterior vitrectomy, we believe that this would not be a serious impediment. However, a surgeon preparing to perform this technique for the first time should consider the possibilities of converting to larger incision extracapsular cataract extraction (ECCE) and may also benefit from having corneal donor tissue available to perform PKP if needed. Visual acuity and function may be ultimately limited by the corneal opacity in an otherwise normal eye. For the above reasons, patients must be extensively counseled on the surgical options including alternative forms of ECCE and the triple procedure. Specifically, they must have realistic expectations and understand that PKP may still be required to optimize visual acuity. Finally, newer instrumentation (eg, chopper, spatula, or phaco tip equipped with fiber-optic endoillumination) may improve visualization irrespective of corneal opacity and increase patient comfort in routine phacoemulsification.

In conclusion, we describe an additional use for transcorneal fiber-optic illumination to facilitate cata-

ract extraction. In this small case series, the technique improved visual acuity and was without complications in all patients. Improvements in technique and instrumentation should lead to more options and better clinical outcomes in patients with cataract and corneal opacification.

### References

1. Parel J-M, Machemer R, Aumayr W. A new concept for vitreous surgery. 4. Improvements in instrumentation and illumination. *Am J Ophthalmol* 1974; 77:6–12
2. Saragas S, Krah D, Miller D. Improved visualization through cataracts using intravitreal illumination. *Ann Ophthalmol* 1984; 16:311–313
3. Mansour AM. Anterior capsulorhexis in hypermature cataracts [letter]. *J Cataract Refract Surg* 1993; 19:116–117
4. Rao SK, Padmanabhan P. Capsulorhexis in eyes with phacomorphic glaucoma. *J Cataract Refract Surg* 1998; 24:882–884
5. Bhattacharjee K, Bhattacharjee H, Goswami BJ, Sarma P. Capsulorhexis in intumescent cataract. *J Cataract Refract Surg* 1999; 25:1045–1047
6. Vajpayee RB, Bansal A, Sharma N, et al. Phacoemulsification of white hypermature cataract. *J Cataract Refract Surg* 1999; 25:1157–1160
7. Malbran ES, Malbran E, Buonsanti J, Adrogué E. Closed-system phacoemulsification and posterior chamber implant combined with penetrating keratoplasty. *Ophthalmic Surg* 1993; 24:403–406
8. Byrnes GA, Antoszyk AN, Mazur DO, et al. Photic maculopathy after extracapsular cataract surgery; a prospective study. *Ophthalmology* 1992; 99:731–737; discussion by AR Irvine, 737–738